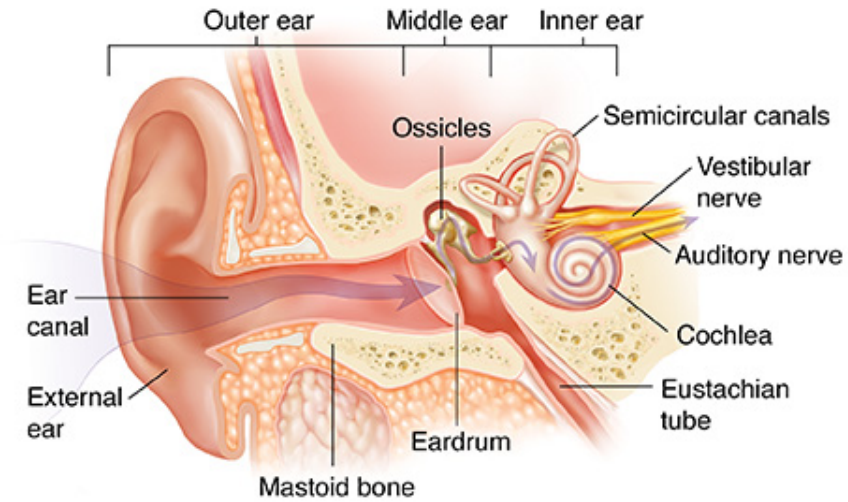


Anatomy of the Ear



Adapted from: https://www.fairview.org/Patient-Education/Articles/English/a/n/a/t/o/Anatomy_of_the_Ear_83594

Ear Structure	Outer Ear	Middle Ear	Inner Ear
Anatomical parts	<ul style="list-style-type: none"> ● External auditory meatus 	<ul style="list-style-type: none"> ● Eardrum (Tympanic membrane) ● Ossicles (malleus, incus, and stapes) ● Eustachian tube 	<ul style="list-style-type: none"> ● Vestibule ● Semicircular canals ● Cochlea ● Auditory nerve (the eighth pair of cranial nerves composed of vestibular nerve and cochlear nerve: vestibulocochlear nerve)